

Bilateral Mooren's Ulcer with perforation and Iris prolapse

Uday Gajiwala¹, Jyotsom Ganatra², Rajesh Patel¹, Parin Shah¹, Rohan Chariwala¹

1. SEWA Rural, Jhagadia-393110, Dist.-Bharuch, Gujarat, INDIA, Phone-(02645)220021,

2. Department of Ophthalmology, Kaiser-Permanente Medical Center, San Rafael, California 94903- USA

Mooren's Ulcer is an idiopathic, rapidly progressive, painful peripheral ulcerative keratitis with no associated scleritis. It's a diagnosis of exclusion which means all other diagnosable systemic disorders that could be responsible for the progressive destruction of cornea must be ruled out. The etiology of Mooren's Ulcer remains uncertain. However, recent studies indicate that it is an autoimmune disease directed against a specific target molecule in the corneal stroma, triggered in genetically susceptible individuals by one of several possible mechanisms. A 40 years old female presented to us on 25th January 2008 from rural tribal area of Sagbara with bilateral peripheral ulcerative keratitis with perforation and iris prolapse in right eye. She is known case of diabetes mellitus for last seven years. Diagnosis of Mooren's ulcer was made after she underwent extensive medical and laboratory testing to rule out an infectious or systemic cause of corneal melt. She benefited by right eye patch graft, left eye tissue adhesive with BCL application, Both eyes conjunctival peritomy and immunosuppressive drugs along with control of diabetes. This case report aims to highlight the diagnosis and treatment of Mooren's ulcer.

Case Report

A 40 year old female from rural tribal area of Sagbara with low socio economical status presented to us on 25th January 2008 with complaint of decreased vision, redness, watering, ocular pain and photophobia in both eyes for last 2 months more so in right eye for last one week. She was having diabetes mellitus for last seven years which was controlled by medication. There was no history of trauma, joint pain.

On examination, best corrected visual acuity in right eye was 6/36 and in left eye, it was 6/24. There was inferior crescent of corneal thinning involving 6 clock hours (3-9 o'clock) with limbal involvement but no associated scleritis. In right eye, there was a perforation with Iris prolapse at 6-7 o'clock position. In both eyes, there was overhanging edge infiltrated with white cells and spreading towards centrally and circumferentially. It was positive for fluorescein stain indicating overlying epithelial defect. The pupil was peaked inferotemporally in right eye due to perforation and in left eye due to impending perforation. There were no signs of secondary infection and/or Iritis on examination. Dilated Indirect ophthalmoscopy was normal in both eyes. (No diabetic retinopathy)

Presentation

She was investigated to rule out systemic disease causing peripheral ulcerative keratitis. RBS was 301 mg/kg showing

uncontrolled diabetes mellitus on the day of presentation.

Investigations done – Hemogram with ESR, Urine routine and microscopy, VDRL, RA factor, HCV, X- ray chest and Joints, SGPT, ANCA, ANA, HBsAg, Scraping of the ulcer are done, which were normal.

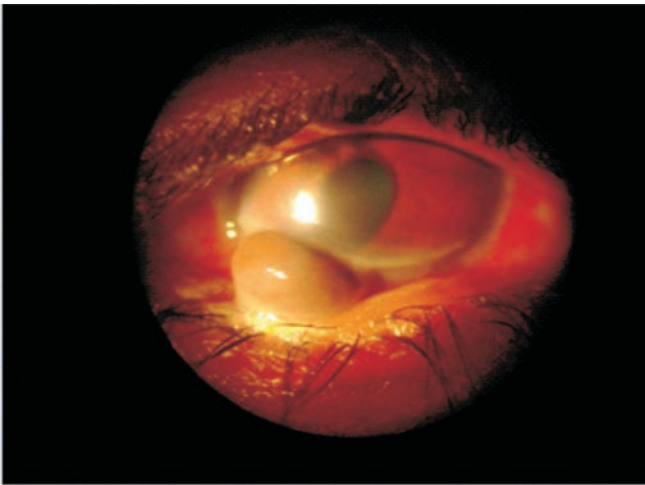
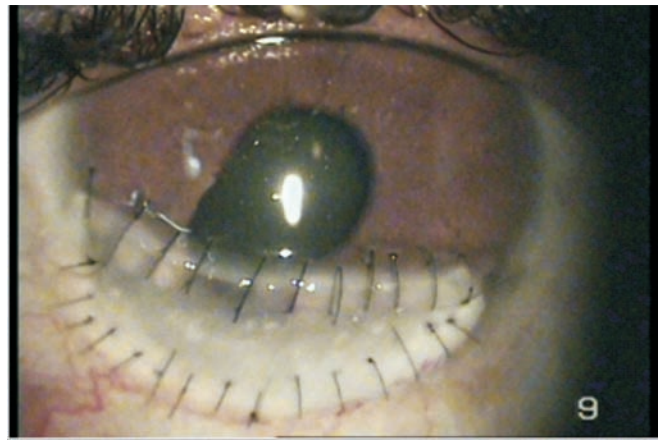
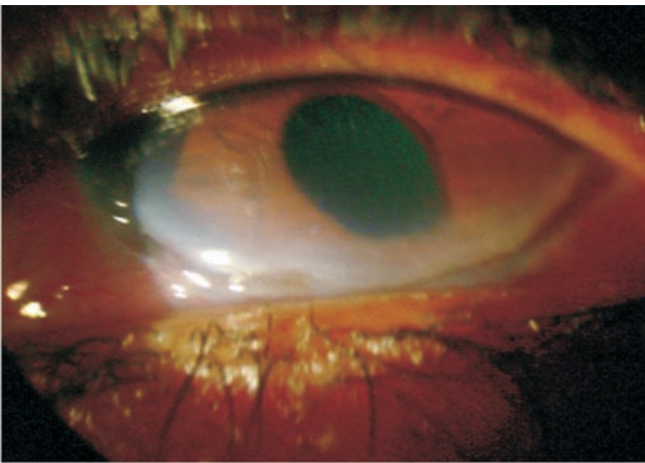
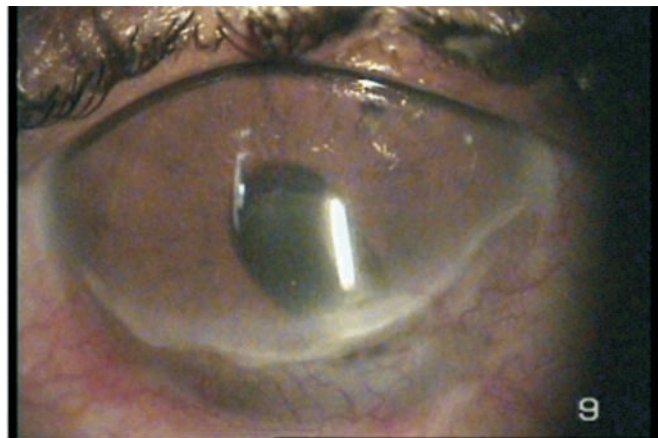
She was referred to her physician to control diabetes mellitus as well as to rule out systemic disorders causing peripheral ulcerative keratitis. She was placed on Insulin Injections to control DM.

After excluding systemic diseases associated with peripheral ulcerative keratitis, A diagnosis of Bilateral Mooren's ulcer was made and systemic immunosuppressive therapy was started with oral methotrexate 10 mg once a week and oral systemic steroids at a dose of 1.5 mg / kg / day.

Right eye Iris abscission (of prolapsed part) with patch graft (free Hand) was done after controlling diabetes mellitus. Tissue adhesive with Bandage Contact Lens Application with conjunctival peritomy was done in left eye.

Locally she was started on Prednisolone eye drops 2 hourly, Ofloxacin eye drops 4 times a day, timolol maleate eye drops twice a day, 2 % HPMC eye ointment three times a day.

Tissue Adhesive and Bandage Contact Lens were removed

*Right Eye:**RE-After 6 Months Follow Up:**Left Eye:**LE-After 6 Months Follow Up:*

after 6 weeks in left eye. It was nicely epithelialized and scarred without any overhanging edge. Right eye patch graft is doing well after 6 months.

Best corrected visual acuity in right eye 6/18 and left eye 6/18 after 6 months follow up.

Discussion

Although the diagnosis of Mooren's ulceration may be difficult when a patient first presents with PUK the clinical appearance is characteristic. However, a thorough medical history, physical examination and appropriate laboratory investigations must be performed to rule out underlying systemic conditions causing PUK, since Mooren's Ulcer is a diagnosis of exclusion.

Mooren's ulcer was first described by Bowman in 1849[1] and then by McKenzie in 1854 as "Chronic serpiginous ulcer of cornea or ulcus roden"[2]. Mooren's name, however, became attached to this rare disorder because of his publication of cases in 1863 and 1867[3]. He was the first to clearly describe this insidious corneal problem and define it as a clinical entity. Nettleship[4] summarized the accumulated reported experience with the disorder in a classic article.

Mooren's ulcer is idiopathic by definition, occurring in complete absence of any diagnosable systematic disorder that could be responsible for progressive destruction of the cornea with no associated scleritis.

Its exact pathophysiology remains uncertain, although a growing body of evidence indicates that it is an autoimmune disease directed against a specific target molecule in the corneal stroma resulting in its destruction by degradative enzymes, which are released primarily by neutrophils attracted into the area by diverse stimuli [12,13], probably triggered in genetically susceptible individual by one or several mechanisms.

Wood and Kaufman having reported 9 cases concluded that there were two clinical types of Mooren's ulcer[5]. The first limited type, is usually unilateral, with mild to moderate symptoms, generally responds well to medical and surgical treatment. This type is believed to occur in older patients and has become known as typical or benign Mooren's ulcer. In contrast, the second type is bilateral, with relatively more pain and generally a poor response to therapy in younger patients, became known as atypical or malignant, Mooren's ulcer. The benign type is bilateral in 25% of patients and the malignant type is bilateral in 75 % of Patients.

Keitzman[6] published a series of 37 cases of progressive Mooren's ulcer in Nigeria affecting primarily healthy men between age of 20 and 30 yrs and the clinical course was very rapid. Perforation occurred in 36% of the patients. As a result, the generalized belief has developed that the progressive and relentless atypical form of Mooren's ulcer has a predilection for young men of African origin.

Lewallen and Courtright[7], in their published series of Mooren's ulcer, suggest that younger patients had bilateral disease less frequently than older patients (1.5:1) regardless of race. Although they found that men were 1.6 times more likely to have Mooren's ulcer than were women.

Different entities have been associated with Mooren's ulcer, often leading to conjecture that there may be a causal relationship.

An association with helminthiasis has been suggested in Nigeria[8], Schanzlinp[9] speculated that the antigen antibody reaction to helminth toxin deposited in peripheral cornea provoked the inflammation and ulceration. Recently in 2 patients with bilateral Mooren's ulcers chronic hepatitis with infection C was documented[10,11] and they improved after treatment of the hepatitis C with interferon $\alpha 2\beta$. The authors proposed that molecular mimicry may be involved, with the hepatitis C virus stimulating an autoimmune response to corneal antigens through cross reacting epitopes.

Based on the clinical presentation[20] and the low dose anterior segment fluorescein angiographic findings, there seem to be three distinct varieties of Mooren's ulceration

1. Unilateral Mooren's ulceration (UM), characterized by an excessively painful progressive corneal ulceration in one eye in elderly patients, associated with non perfusion of the superficial vascular plexus of the anterior segment.
2. Bilateral aggressive Mooren's ulceration (BAM), which occurs in young patients, progresses circumferential and only later, centrally in the cornea. Angiography shows vascular leakage and new vessel formation which extends into the base ulcer.
3. Bilateral indolent Mooren's ulceration (BIM), which usually occurs in middle aged patients presenting with progressive peripheral corneal guttering in both eyes, with little inflammatory response. There is no change from the normal vascular architecture on angiography except an extension of new vessels into the ulcer.

DD

- Rheumatoid arthritis
- Wegener's Granulomatosis

- Polyarteritis Nodosa
- Other collagen vascular diseases
- Inflammatory bowel disease
- Giant cell Arteritis
- Staphylococcal Marginal Keratitis
- Local infections causes
- Terrien's degeneration
- Pellucid degeneration
- Ocular Rosacea

Treatment

Today, most experts agree on stepwise approach in management of Mooren's ulcer[19]].

1. Topical Steroids
2. Conjunctival Resection
3. Systemic immuno suppressive
4. Additional Surgical Procedure
5. Rehabilitation

Goals

To arrest the destructive process and to promote healing and re-epithelialization of the corneal surface[15-18].

Steroids

Initially: Intensive topical steroids

Prednisolone acetate 1% eye drop

One hourly

In association with

Topical Cycloplegics

Prophylactic Antibiotics

If epithelial healing does not occur within 2-3 days, the frequency of topical steroids can be increased to every half hour.

Once healing occurs, the frequency can be reduced and tapered slowly over a period of several months.

Such management, especially in unilateral, benign form has met with good results.

Topical cyclosporine-A therapy (0.5% solution) also found useful in some studies.

Systemic steroids

Oral pulse therapy

60-100 mg daily of oral Prednisolone is indicated when topical therapy is ineffective after 7-40 days.

When topical steroids may be dangerous because of precariously deep ulcer or infiltrate [[14, 22].

Topical tetracycline may be used for anticollagenolytic properties.

A therapeutic soft contact lens or patching of eye may be

beneficial when ulcer is deep.

Conjunctival Resection

- If ulcer progresses despite steroid regimen, conjunctival resection should be performed [15-18].
- Under topical or sub conjunctively anesthesia, this consists of conjunctival excision to bare sclera extending at least 2 clock hours to either side of peripheral ulcer and approximately 4 mm posterior to the corneoscleral limbus and parallel to the ulcer[23]. The overhanging lip of ulcerating corneas may also be removed. Post operatively a firm pressure dressing should be used.

The rationale of this procedure

Conjunctiva adjacent to the ulcer contains inflammatory cells that may be producing antibodies against the cornea and cytokines which amplify the inflammation and recruit additional inflammatory cells.

Multiple resections may be necessary.

Systemic immuno suppressive therapy

Indication

Bilateral or progressive Mooren's ulcer that fails to preceding therapeutic attempts will require systemic cytotoxic therapy to bring a halt to the progressive corneal destruction

Commonly used agents

Cyclophosphamide – 2 mg / kg / day

Methotrexate (7.5 – 15 mg once a week)

Azathioprine (2 mg / kg body weight / day)

The degree of fall in white blood cell count is considered as the most reliable indicator of immunosuppression produced by cyclophosphamide.

Most authors believe that the evidence for the efficacy of systematic immune suppressive chemotherapy for progressive bilateral Mooren's ulcer is quite strong, and further believe that such treatment should be employed sooner rather than later in the care of such patients, before the corneal destruction, has become too extensive to need for surgery.

Adverse effects of these cytotoxic and immunosuppressive medications, such as anemia, alopecia, nausea, nephrotoxicity, are likely and it must be administered in close observation of physician.

Additional surgical procedures

Small perforations / Impending perforation may be treated with application of tissue adhesive – isobutyl cyanoacrylate and placement of a soft contact lens to provide comfort and to prevent dislodging of the glue.

When a perforation is too large for tissue adhesive to seal the leak, some type of patch graft will be necessary. This may range from a small tapered plug of corneal tissue to a penetrating keratoplasty.

Rehabilitation

Once the active ulceration has stopped and the remaining cornea has been completely opacified, it is possible to perform PK on these patients, even in the face of a thinned and vascularized cornea.

Because of the immune system's remarkable memory, surgical attempts at rehabilitation in Mooren's ulceration, should be done only with concurrent immunosuppressant, even when the active disease has been arrested, or is burnt out because attempts at penetrating keratoplasty often are associated with recurrence and graft failure.

Conclusion

Bilateral Mooren's ulcer in young patients can progress rapidly in a circumferential fashion towards the center of the cornea and can present with perforation and Iris prolapse early in a course of disease. Though clinical appearance is characteristic, Mooren's Ulcer remains a diagnosis of exclusion and systemic diseases associated with PUK must be ruled out. Current treatment options and work up have resulted in a significant improvement in the prognosis of patients with Mooren's Ulcer. With appropriate management, the eyes can usually be salvaged and visual loss can be minimized. The keys to appropriate treatment are early diagnosis, judicious use of topical as well as systemic steroids, immunosuppressives, and the use of tissue glue and patch grafting as indicated by the clinical scenario.

References

1. Bowman W: Case 12, pl12 in the parts concerned in the operations of the eye (1849), cited by Nettleship E: Chronic Serpiginous Ulcer of the Cornea (Mooren's ulcer). *Trans Ophthalmol Soc UK* 22:103-144,1902
2. McKenzie H: *Disease of the Eye*. 1854, p 631.
3. Mooren A: *Ulcus Rodens*. *Ophthalmiatische Beobachtungen*. Berlin, A. Hirschwald:107-110, 1867
4. Nettleship A, Brkic S, Vackonic S: Chronic Serpiginous Ulcer of the Cornea (Mooren's ulcer). *Trans Ophthalmol Soc UK* 22:103 - 144, 1902
5. Wood T, Kaufman H: Mooren's ulcer. *Am J Ophthalmol* 71:417-422, 1971
6. Keitzman B. Mooren's ulcer in Nigeria. *Am J Ophthalmol* 65:679-685, 1968
7. Lewallen S, Courtright P: Problems with current concepts of the epidemiology of Mooren's corneal ulcer. *Ann Ophthalmol* 22:52-55, 1990
8. Majekodunmi AA. Ecology of Mooren's ulcer in Nigeria. *Doc Ophthalmol* 49:211-219, 1980

9. Schanzlin D: Mooren's Ulceration. In: Smolin G, Thoft R, eds. *The cornea*. Boston. Little brown 1994, pp 408-414.
10. Wilson S, Lee W, Murakami C et al. Mooren's type Hepatitis C virus-associated corneal ulceration. *Ophthalmology* 101:736-745, 1994
11. Moazami G, Auran J, Florakis G et al: Interferon treatment of Mooren's ulcers associated with hepatitis C. *Am J Ophthalmol* 119:365-366, 1995
12. Brown S. Mooren's ulcer: Histopathology and proteolytic enzymes of adjacent conjunctiva. *Br J Ophthalmol* 59:670-674, 1975
13. Young R, Watson P: Light and electron microscopy of corneal melting syndrome (Mooren's Ulcer). *Br J Ophthalmol* 66:341-356, 1982
14. Ferguson E III, Carreno O: Mooren's ulcer and delimiting keratotomy. *South Med J* 62:1170-1175, 1969
15. Chow C, Foster CS: Mooren's ulcer. *Int Ophthalmol Clin* 36:1-13, 1996
16. Dinzis P, Mondino B: Management of non-infectious corneal ulcers. *Surv Ophthalmol* 32:94-110, 1987
17. Mondino B: Inflammatory diseases of the peripheral cornea. *Ophthalmology* 95:463-472, 1988
18. Robin G, Schanzlin D, Verity S et al. Peripheral corneal disorders. *Surv Ophthalmol* 31:1-36, 1986
19. Sangwan VS, Zafirakis P, Foster CS. Mooren's ulcer: Current concepts in management. *Indian J Ophthalmol* 1997;45:7-17
20. Watson PG. *Eye*. 1997; 11 (Pt 3):349-56.
21. Seino JY, Anderson SF. *Optom Vis Sci* 1998 Nov; 75(11):783-90.
22. Frangieh T, Kenyon K: Mooren's ulcer. In: Brightbill FS, ed. *Corneal Surgery: Theory, technique, and tissue*, ed 2. St Louis: Mosby 1993, pp 328-335.
23. Foster CS: Immunologic disorders of the conjunctiva, cornea and sclera. In: Albert DA & Jakobiec FA, eds. *Principles and Practice of Ophthalmology*. Philadelphia: Saunders: 1994, pp 200-203.